NOVARTIS

[illegible]

[illegible]TSC[illegible]

[illegible]

[illegible]

[illegible]

[illegible]

[illegible]

[illegible]

[illegible]

[illegible]

[illegible][1][illegible]

[illegible]

[illegible]50[illegible]**1**[illegible]**2**[illegible][2][illegible]

Image

図1　網膜過誤腫の発現時期

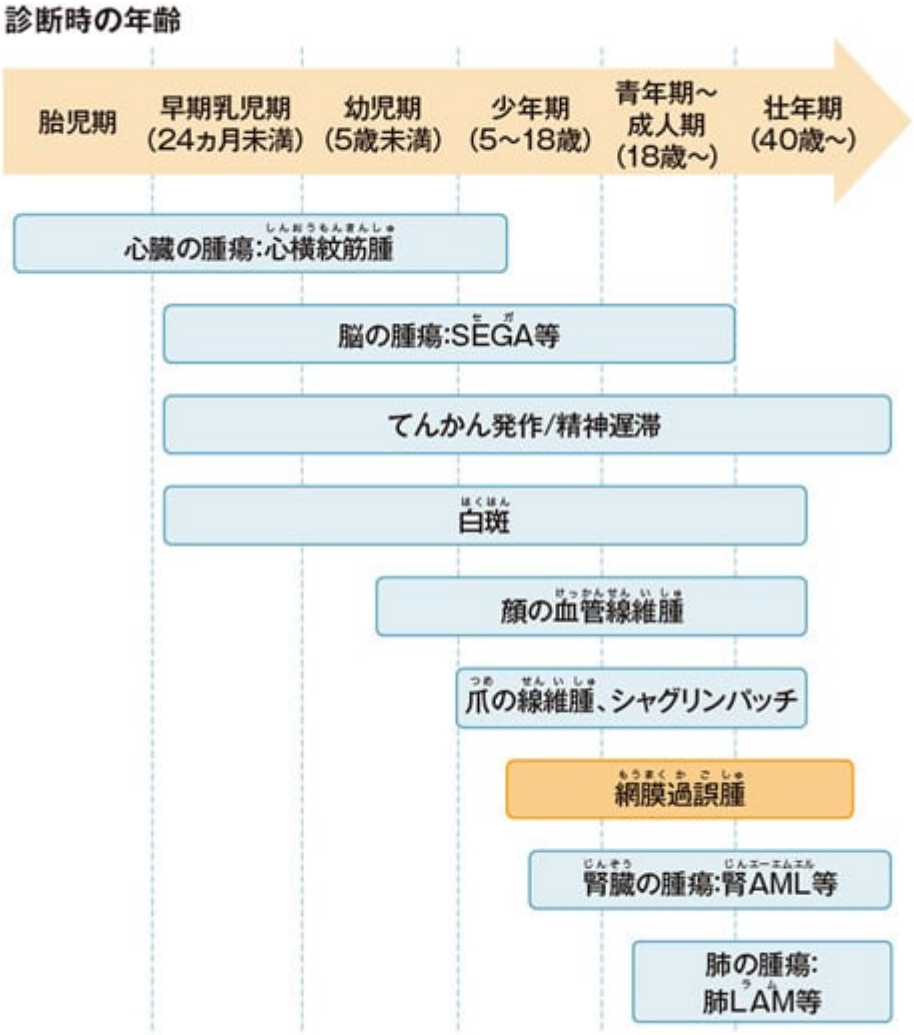

大野耕作, 平山義人, 松井氏豊次郎, 編. 知的障害者の健康管理マニュアル. 東京: 診断と治療社, 2007; 83.
金田 眞理, 他. 日皮会誌 2018; 128: 1-16. より作図

Image

図2　年齢期ごとの網膜過誤腫の発現率（海外データ）

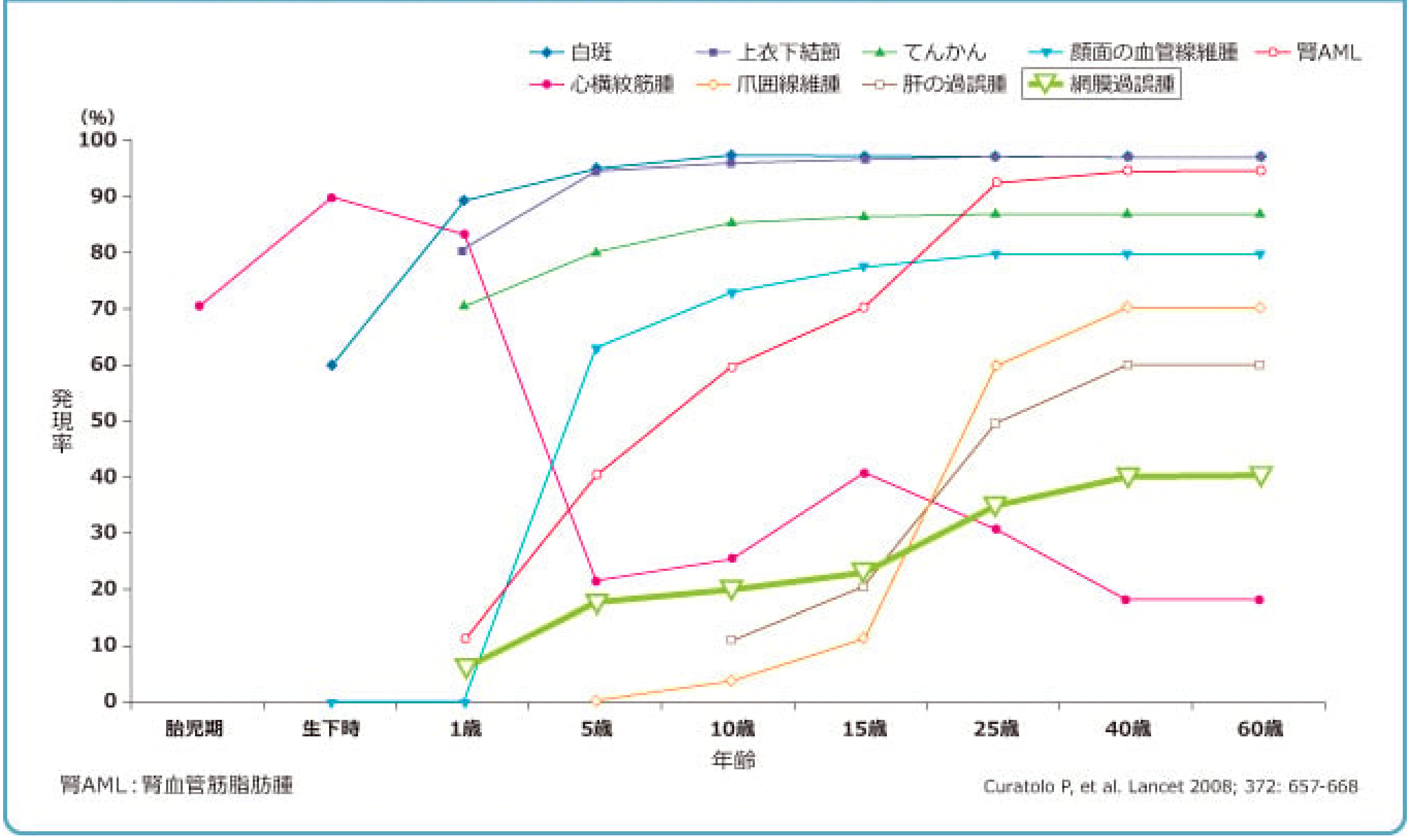

[illegible]

[illegible]

[illegible]

[illegible]1[illegible][3][illegible]
[illegible][1][illegible] [illegible][illegible][illegible]

[illegible]

[illegible]photocoagulation[illegible]**3**[illegible]
[illegible][3][4][illegible]

Image

図 3

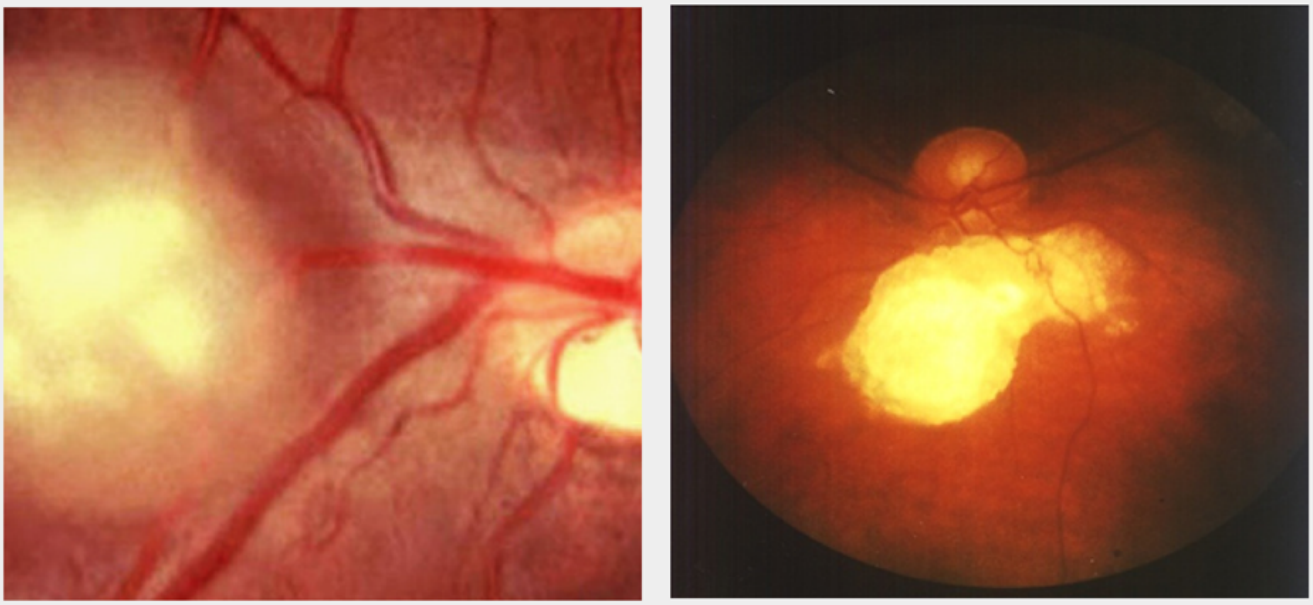

Adapted from Roach et al. 2004

※異なる症例の写真です。

Image

図 3

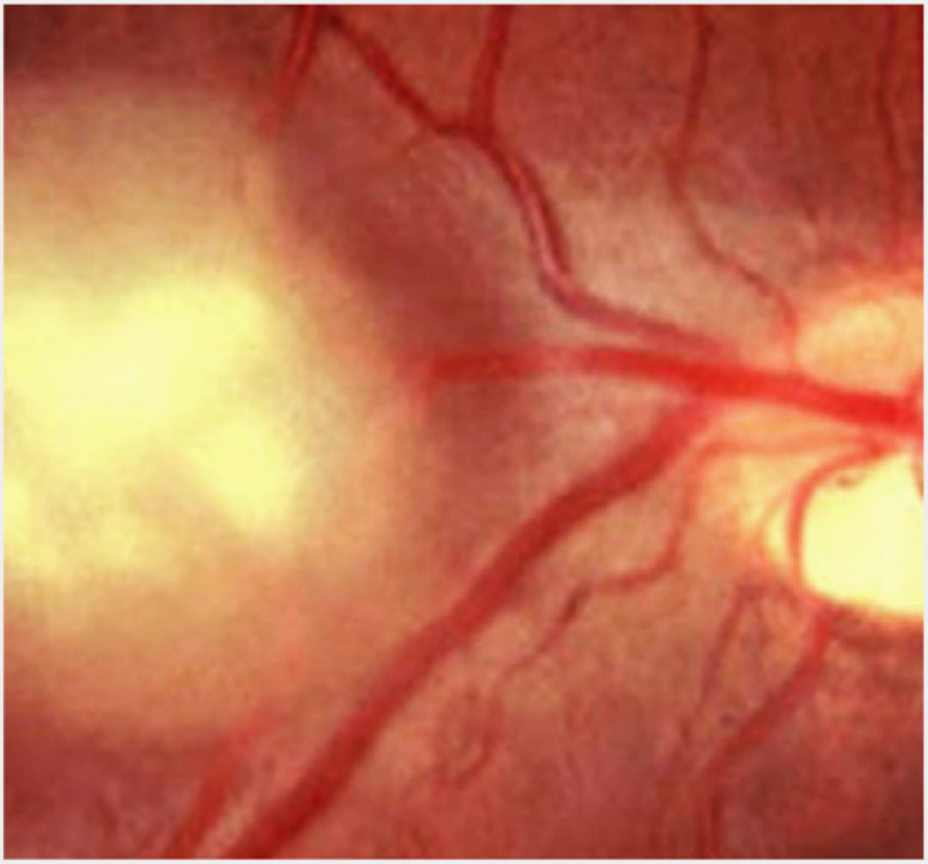

Adapted from Roach et al. 2004

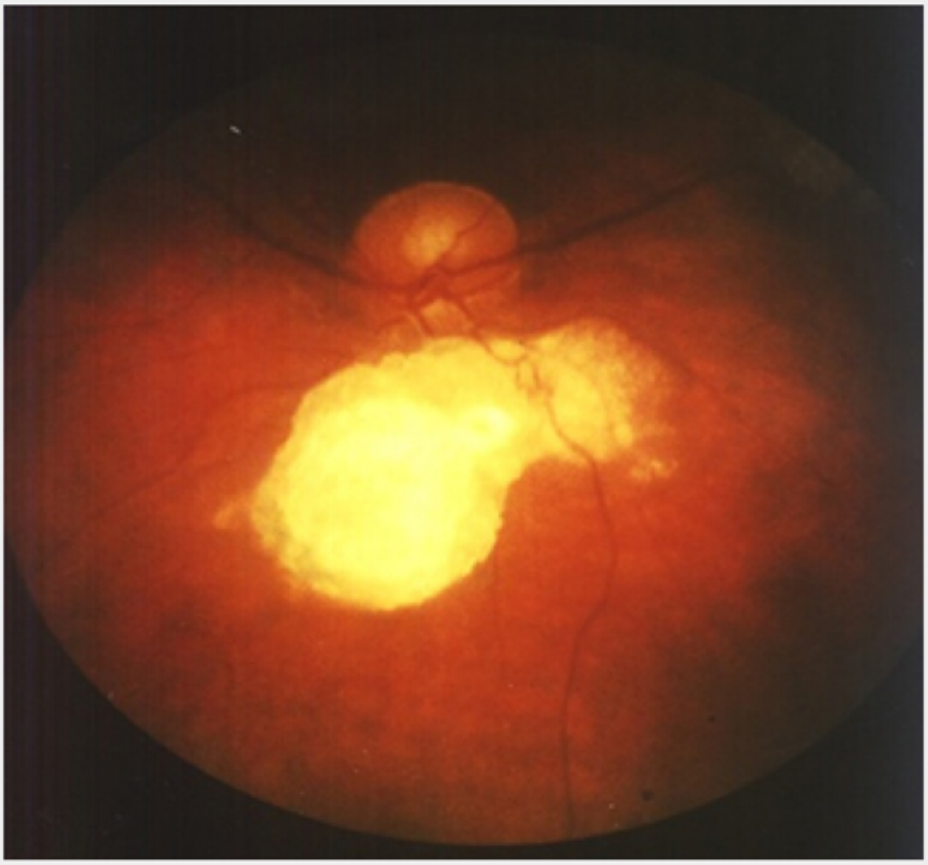

※異なる症例の写真です。

□□□□

1□Northrup H, et al. Pediatr Neurol 2013; 49: 243–254
2) Curatolo P, et al. Lancet 2008; 372: 657-668
3) □□□□, □. □□□□ 2018; 128: 1-16
4) □□□□, □. □□□□ 2008; 118: 1667-1676

□□□□□□□□□□□□□□□□

□□□□□□

Source URL: *https://www.loadtest.pro.novartis.com/products/afinitor/tsc/symptom_10*